

# Absence of right common carotid artery in a patient with common origin of the innominate artery and left common carotid artery

Giovanna Golin Guarinello, MD,<sup>a</sup> Francisco Eduardo Coral, MD, MSc,<sup>a,b,c</sup> Carlos Alberto Engelhorn, MD, PhD,<sup>b,c</sup> Sarah Folly Machado, MS,<sup>b</sup> Amanda Prokopenko, MS,<sup>b</sup> and Sergio Xavier Salles-Cunha, PhD,<sup>c</sup> Curitiba, Paraná, Brazil

## ABSTRACT

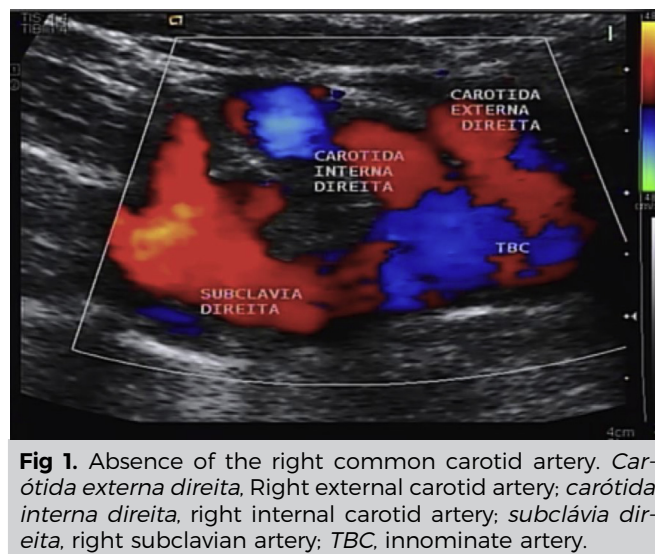
A 50-year-old woman was referred to the noninvasive vascular laboratory for carotid artery evaluation because of a bruit in the neck. Color Doppler ultrasound examination demonstrated absence of the right common carotid artery and parallel internal and external carotid arteries originating at the brachiocephalic trunk. Computed tomography angiography further described anomalous anatomy, demonstrating a common origin of the innominate artery and left common carotid artery. Knowledge of such unusual anatomy may become valuable in future evaluation or treatment of this patient. (J Vasc Surg Cases and Innovative Techniques 2020;6:46-9.)

**Keywords:** Carotid artery; Common origins of the innominate artery and left common carotid artery; Bovine arch; Cerebrovascular disease

Absence of a common carotid artery is a rare finding during initial physical examination or even basic screening or diagnostic ultrasound examinations with approximately 35 reported cases.<sup>1,2</sup> Besides the low frequency of such anatomic variation, most patients are asymptomatic. The combination of absence of the common carotid artery with an abnormal aortic arch anatomy is an even rarer condition to be detected in a vascular clinic or ultrasound vascular laboratory, with a single case reporting the same variation although on the left side.<sup>3-7</sup> A case of an asymptomatic 50-year-old woman having carotid artery screening is reported herein because of the extreme rarity of the event: right common carotid artery absence together with a common origin of the innominate artery and left common carotid artery. The patient has agreed to have images and case details published.

## CASE REPORT

A 50-year-old woman without signs or symptoms of cerebrovascular disease was directed to the noninvasive vascular



**Fig 1.** Absence of the right common carotid artery. *Carótida externa direita*, Right external carotid artery; *carótida interna direita*, right internal carotid artery; *subclávia direita*, right subclavian artery; *TBC*, innominate artery.

laboratory because her primary physician found a bruit on the right side of her neck.

**Color flow duplex ultrasound.** Color Doppler ultrasound was initiated following standard carotid procedures. An Acuson Antares ultrasound system (Siemens Healthcare, Issaquah, Wash) and a linear (7-10 MHz) transducer were used. Three vessels were detected in parallel (Fig 1): the right jugular vein (*in blue*) and two arteries, each one identified according to flow characteristics—the medially located external carotid artery with oscillatory flow and low end-diastolic velocities (Fig 2, A) compared with the low-resistance flow of the laterally placed internal carotid artery (Fig 2, B). A right common carotid artery bifurcation and a right bulb were not detected with the linear transducer as is usually expected. In addition, a convex transducer did not reveal a low bifurcation of the right common carotid artery. The unusual finding was the detection of independent origins for the right internal and external carotid

From the Department of Angiology, Hospital Santa Casa of Curitiba<sup>a</sup>; the Department of Angiology, School of Medicine, Pontifical Catholic University of Paraná<sup>b</sup>; and the Angiolab Noninvasive Vascular Laboratory.<sup>c</sup>

Author conflict of interest: none.

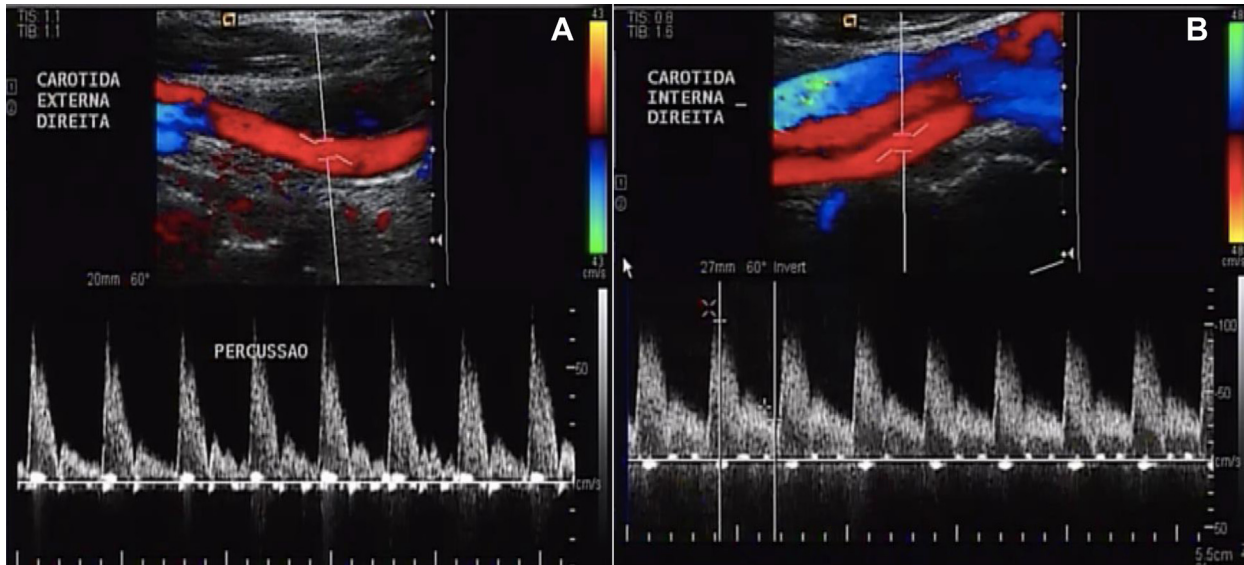
Correspondence: Giovanna Golin Guarinello, MD, Hospital Santa Casa de Curitiba, Praça Rui Barbosa, 694 Centro, 80010-030 Curitiba, Paraná, Brazil (e-mail: [giovanna.guarinello@yahoo.com.br](mailto:giovanna.guarinello@yahoo.com.br)).

The editors and reviewers of this article have no relevant financial relationships to disclose per the Journal policy that requires reviewers to decline review of any manuscript for which they may have a conflict of interest.

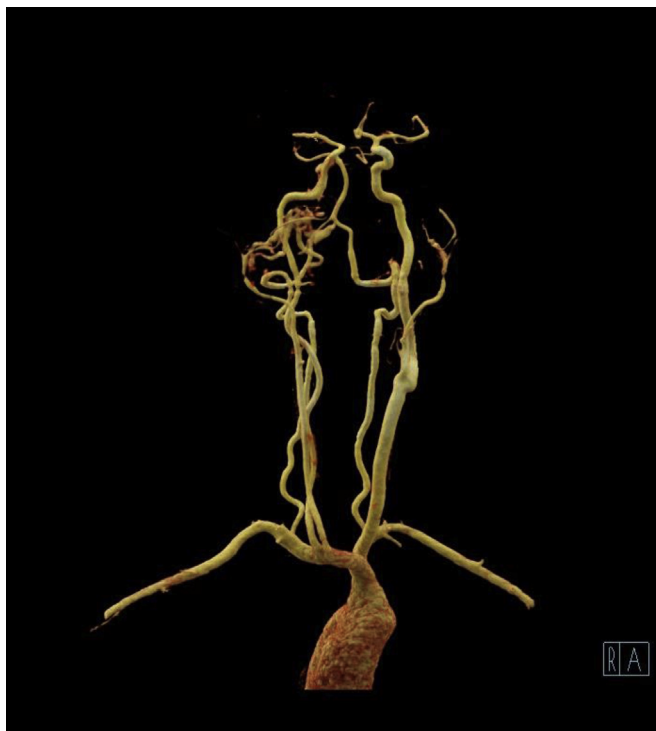2468-4287

© 2019 The Author(s). Published by Elsevier Inc. on behalf of Society for Vascular Surgery. This is an open access article under the CC BY-NC-ND license (<http://creativecommons.org/licenses/by-nc-nd/4.0/>).

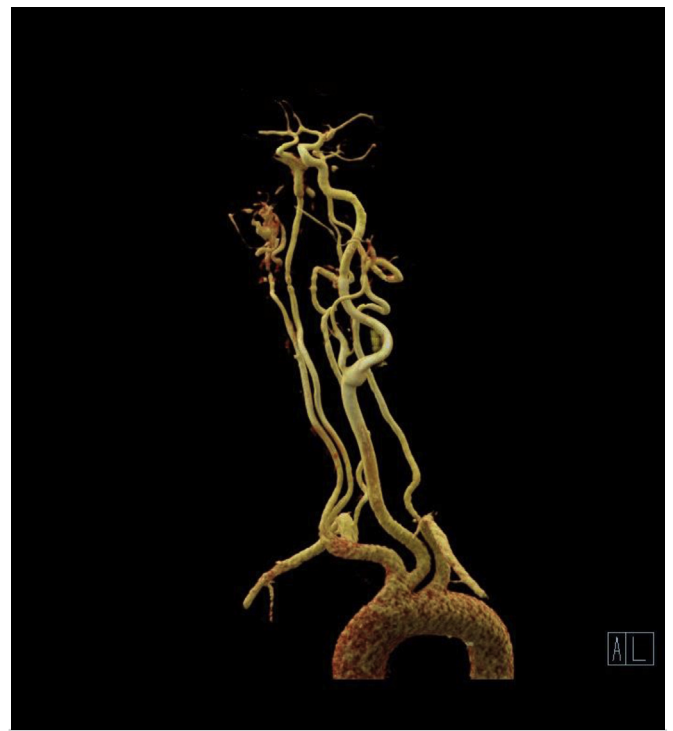<https://doi.org/10.1016/j.jvscit.2019.10.006>



**Fig 2. A,** Right external carotid artery flow. **B,** Right internal carotid artery flow.



**Fig 3.** Computed tomography angiography (CTA) reconstruction: anomalous origin of the internal and external carotid arteries on the right.

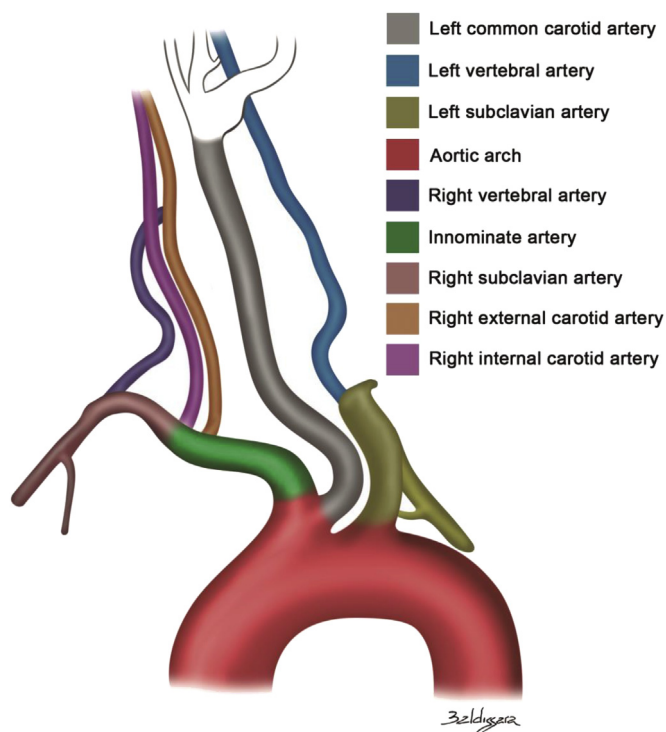


**Fig 4.** Computed tomography angiography (CTA) reconstruction: common origin of the innominate artery and left common carotid artery.

arteries at the brachiocephalic trunk. Color flow duplex ultrasound did not reveal significant disease. The main finding was therefore the variant anatomy.

**Computed tomography angiography (CTA).** To provide additional information about anatomic variants, particularly of the aortic arch, that could interfere with future diagnostic

and even therapeutic conditions of the patient, CTA was contemplated because color duplex ultrasound is limited to study of the central vessels of the aortic arch. CTA with a 128-slice scanner (Siemens Healthcare, Erlangen, Germany) confirmed the anomalous origin of the internal and external carotid arteries on the right (Fig 3). In addition, another unusual finding was documented: the origin of the left common



**Fig 5.** Absence of right common carotid artery and common origin of the innominate artery and left common carotid artery.

carotid artery from the proximal brachiocephalic trunk, pointing to a common origin of the innominate artery and left common carotid artery (Fig 4). Fig 5 demonstrates both anatomic variations.

## DISCUSSION

Absence of a common carotid artery was described by Malacarne in 1784.<sup>5,8,9</sup> Prevalence of such a finding is similar on the right or left and higher in women.<sup>2,10-12</sup> In general, such anatomic variations do not cause symptoms and have been detected during imaging examinations.<sup>10</sup>

Color Doppler ultrasound can suggest the lack of a common carotid artery bifurcation.<sup>13,14</sup> A complete diagnostic ultrasound examination, however, requires an additional protocol and the use of a convex/cardiac transducer to study the aortic arch and the subclavian arteries. A more complete evaluation is usually performed with CTA or magnetic resonance angiography.<sup>10,15</sup> Images with multiple rotations and translations exemplify anatomic variations and provide reliable information in cases requiring catheterization and endovascular procedures.

Although the term is a widely used misnomer, “bovine arch” occurs when the left common carotid artery has a common origin with the innominate artery. It is the second most common variant of aortic arch branching and has a prevalence close to 14%.<sup>16,17</sup> Goyal and Sinha<sup>5</sup>

described a case of absent left common carotid artery and a bovine arch origin of the left external carotid artery. The case reported herein is another variation combining the bovine arch and absence of the right common carotid artery.

Such anatomic variations are not necessarily related to indications for treatment of carotid or other arterial disorders of the aortic arch. However, anatomic variations must be considered in the planning of endovascular procedures. Even some operations could be surprisingly affected by such variant anatomy. Noninvasive vascular laboratories, especially those specialized in definitive diagnosis and preoperative mapping beyond basic screening, should have additional protocols, awareness, and specific training to deal with such unusual cases.

## CONCLUSIONS

Variant anatomy of the extracranial carotid arteries, in particular absence of the common carotid artery, especially if it is associated with aortic arch alterations, is rarely observed. Physical examination and color Doppler ultrasound require additional protocols and training to suspect and to detect such findings. CTA and magnetic resonance angiography are requested as needed to complete the examination of arch and carotid anatomic variations.

## REFERENCES

1. Kobayashi D, Natarajan G, Joshi A, Aggarwal S. Congenital absence of bilateral common carotid arteries. *Ann Thorac Surg* 2013;95:719.
2. Braun R, Velayudhan V, Loona J. Absent left common carotid artery in a trauma patient. *J Vasc Interv Radiol* 2017;28:230.
3. Ulger FE, Ulger A, Colak M. Absence of the right common carotid artery: Doppler ultrasonographic and MR angiographic findings. *Vascular* 2014;22:364-7.
4. Quinones G, Srinivasan A. Absence of the right common carotid artery: a rare case without separate origins of the internal and external carotid arteries. *Clin Imaging* 2017;43:184-7.
5. Goyal S, Sinha AK. A rare case of absent left common carotid artery with bovine origin of the left external carotid artery. *BMJ Case Rep* 2016;2016. bcr2016012540.
6. Purkayastha S, Gupta AK, Varma DR, Bodhey NK, Vattoth S. Absence of the left common carotid artery with cervical origin of the right subclavian artery. *AJNR Am J Neuroradiol* 2006;27:708-11.
7. Maybody M, Uszynski M, Morton E, Vitek JJ. Absence of the common carotid artery: a rare vascular anomaly. *AJNR Am J Neuroradiol* 2003;24:711-3.
8. Robert LK, Gerald B. Absence of both common carotid arteries. *AJR Am J Roentgenol* 1978;130:981-2.
9. Cerase A, Rubenni E, Tassi R, Stromillo ML, Venturi C. Absence of the right common carotid artery. *Surg Radiol Anat* 2009;31:815-7.
10. Wood EA, Malgor RD, Labropoulos N. Diagnosing common carotid artery agenesis using duplex ultrasound. *Vasc Endovascular Surg* 2011;45:727-32.
11. Dahn MS, Kaurich JD, Brown FR. Independent origins of the internal and external carotid arteries. A case report. *Angiology* 1999;50:755-60.

12. Bryan RN, Drewyer RG, Gee W. Separate origins of the left internal and external carotid arteries from the aorta. *AJR Am J Roentgenol* 1978;130:362-5.
13. Yim SJ, Ryu JH, Baik JS, Kim JY, Park JH, Han SW. Common carotid artery agenesis: duplex ultrasonographic findings. *J Clin Neurol* 2009;5:149-50.
14. Woodruff WW, Strunsky VP, Brown NJ. Separate origins of the left internal and external carotid arteries directly from the aortic arch: duplex sonographic findings. *J Ultrasound Med* 1995;14:867-9.
15. Cakirer S, Karaarslan E, Kayabali M, Rozanes I. Separate origins of the left internal and external carotid arteries from the aortic arch: MR angiographic findings. *AJNR Am J Neuroradiol* 2002;23:1600-2.
16. Popieluszko P, Henry BM, Sanna B, Hsieh WC, Saganiak K, Pekala PA, et al. A systematic review and meta-analysis of variations in branching patterns of the adult aortic arch. *J Vasc Surg* 2018;68:298-306.e10.
17. Layton KF, Kallmes DF, Cloft HJ, Lindell EP, Cox VS. Bovine aortic arch variant in humans: clarification of a common misnomer. *AJNR Am J Neuroradiol* 2006;27:1541-2.

Submitted Jun 12, 2019; accepted Oct 13, 2019.